



The incidence of gastric lesions in slaughtered pigs in Ibadan, Nigeria

MM Majekodunmi¹, OO Omotosho^{1*}, BO Emikpe² & BE Olufemi¹

¹Department of Veterinary Medicine, University of Ibadan, Nigeria.

²Department of Veterinary Pathology, University of Ibadan, Nigeria.

*Correspondence: Tel.: +2348037806791, E-mail: omotosho.oladipo@ui.edu.ng

Abstract

Information about frequency in the occurrence of gastric lesions in pigs slaughtered in Nigeria appears scanty. A random sampling of stomachs of 100 slaughtered pigs from Bodija abattoir, one of the largest abattoir in south western Nigeria was used for this investigation. The stomachs were examined grossly and the locations of the lesions were noted, tissues were routinely processed and examined histologically. Descriptive statistics and Chi square were employed to analyse data obtained. The predominant lesions observed were those of ulcers with few being nodules of varying sizes and a few erosions. Of the stomachs examined, 11(11%) had acute pin point ulcers while 21(21%) had chronic ulcers. 14(14%) showed healed areas, with nodules while 54(54%) were free from obvious lesions. Majority of the erosions and ulcerations (76%) occurred in the pars oesophagea while the histopathological changes observed are that of ulceration with foci of chronic nodular gastritis and fibrous granulation. There is a possible age predisposition in the occurrence of gastric lesions. The pin point ulcers and chronic nodular gastritis observed showed that most stomach lesions observed in slaughtered pigs in this environment may be due to myriad of factors that need to be further researched on.

Keywords: Erosions, Gastric Lesions, Incidence, Slaughtered pigs, Ulcerations.

Received 24-07-2012

Accepted 10-12-2012

Introduction

Gastric lesions including erosion and ulceration are common conditions in pigs especially the growing pigs (100–200lb [45-90kg]) than breeding animals (Anon, 2012). This condition occurs in swine usually from 1 day old – 8 years of age. However, it is most commonly observed in animals 2-4 months old which correspond to the period of fastest growth in pigs (Anon, 2012). Ulcers, one of the lesions commonly observed in pig stomach affect the *pars oesophagus* causing sporadic cases of acute gastric haemorrhage which often result in either death or slow growth possibly due to chronic ulceration. Unfortunately the primary cause is unknown, there are probable multiple factors involved (Friendship, 1999).

Of the stomach lesions, gastric ulcers have been recognised for many years in man and birds having a worldwide distribution. All domestic and many

captive wild swine are subject to naturally developing gastric ulcers. Among domestic animals, gastric ulcers have been reported in chicken, cattle, horses and swine (Pfeiffer, 1992). Sporadically occurring ulcers were also reported among many wild and captive mammals e.g. jackals, coyotes, antelopes and wild hogs. Stomach ulcers in swine have a worldwide distribution with a high incidence in the United States and Europe (Friendship, 1999). Gastric Ulcers in swine have been diagnosed with increasing frequency since the 1950s (Barbosa *et al*, 1995).

The stomach of the pig is characterised by its great fragility, in particular in the *pars oesophageal* zone close to the cardiac region (Anon, 2012). This region is characterised by the stratified squamous nature of the epithelium lining and lack of secretions, which makes it vulnerable to any external aggression. The

most apparent lesion is hyperkeratosis of diverse degrees accompanied by yellowish tincture of the mucosa due to bilious contamination. If the process continues then deeper erosions appear (Friendship, 1999).

Gastric ulceration in swine is generally believed to be caused by multiple factors. These factors include age, breed, sex, heredity, infection and parasitism, toxicity, trauma, nutrition and management factors (Friendship, 1999). Other workers have been able to establish a relationship between gastric ulceration in pigs and concurrent diseases (Krakowka *et al.*, 1995; Dionissopoulos *et al.*, 2001), nutrition (Wondra *et al.*, 1995; Ayles *et al.*, 1996), management factors (Amory *et al.*, 2006) and *Helicobacter pylori* (Krakowka *et al.*, 1995; Hermann *et al.*, 1995; Cattoli *et al.*, 1999).

Gastric lesions of swine occur more often than are reported in most parts of the world (Makinde & Obwolo, 1990; Krakowka *et al.*, 1995; Hermann *et al.*, 1995; Cattoli *et al.*, 1999) but information about the occurrence in slaughtered pigs in Nigeria appears scanty. This study is undertaken to document the incidence of gastric lesions in slaughtered pigs in Ibadan, Nigeria in order to create awareness on the condition in pigs.

Materials and methods

Study area and sampling technique

The study was conducted in Ibadan, Southwestern Nigeria at the Bodija Municipal Abattoir, the biggest abattoir in Ibadan which serves most parts of the south western Nigeria.

A random sampling of stomachs of 100 slaughtered pigs in five groups based on their sex and age were used for this investigation. The appropriate sample size was determined largely by three factors: (i) the estimated prevalence of the variable of interest (ii) the desired level of confidence and (iii) the acceptable margin of error. Based on a simple random sampling, the sample size required was calculated according to the following formula.

$$n = \frac{t^2 \times p(1-p)}{m^2}$$

Where :

n = required sample size

t = confidence level at 95% (standard value of 1.96)

p = estimated prevalence in the project area was estimated at 95% (0.95) since there was no previous study (as far as the authors know) in Nigeria.

m = margin of error at 5% (standard value of 0.05)

n = (1.96)²(0.95)(0.05)/0.05²

n=73, (100 was used)

The animals were slaughtered between June and July 2011. The pigs were examined before slaughter to ascertain their breed, age, sex and body weight. The breeds were mostly Large white, Hampshire, and other undetermined crosses. The stomach was harvested after slaughter with 2-3 cm of oesophagus and small intestines attached. It was cut along the greater curvature from the cardia to the pylorus and the ingesta discarded. The visceral surface was rinsed with clean water slightly then examined grossly for epithelial thickening, nodules, small focal ulcers, coalescing ulcers, extensive ulcers, and scar tissues. The anatomic position of the pathology was noted.

Lesion assessment

A total of 42 males and 58 females were examined. The identified gastric tissues with lesions were cut along with healthy surrounding tissue. The samples were taken to the histology laboratory in sample bottles containing 10% formalin for routinely processing and examination.

Although the histopathology was not scored using ulcer scale but the presence of inflammatory cells were noted. Histopathological observations were made on the various parts of the gastric mucosa: glandular lumen, surface epithelium, glandular epithelial cells, and interglandular connective tissue.

Statistical analysis

Descriptive statistics was used to describe the percentage occurrence while chi square was employed for the significance.

Results

Pathology

Grossly, the predominant lesions observed were those of ulcers (95%) with few being nodules of varying sizes and a few erosions with 35% of the lesion in the pars oesophagea of the stomach examined. The ulcers were more pin point while the nodules varied between 0.5 mm to 1.0 mm. 11(11%) had acute pin point ulcers while 21(21%) had chronic ulcers. 14(14%) showed healed areas, with nodules while 54(54%) were free from obvious lesions (Fig 1). The lesions were commonly observed in the male growers than females but the difference was not significant while there was a significant difference between the non pregnant and pregnant females. The distributions of the pigs examined in relation to their sex, age, anatomic location of the gastric lesions (Table 1).

The lesions were predominantly ulcers with few being nodules and a few erosions. The lesions were observed more in young males than female with young males having 56.3% lesion occurrence than corresponding young female. In one year to 3 years pigs, there was a significant higher occurrence in female non pregnant sows. A larger percentage of the lesions were observed in the pars oesophagea. Although the histopathology was not scored, the most striking changes were glandular degeneration with accumulation of lymphoplasmacytic cells, fibrosis of the lamina propria mucosae and lymphoid

follicles. The isolated intraepithelial lymphocytes were frequently observed; in some cases, however, clusters of cells were found within the surface epithelium. In some degenerating glands, increased numbers of lymphocytes, macrophages and plasma cells, were observed (Plates III, IV & V). Lymphocytes, plasma cells, macrophages, globular leucocytes were noted on various parts of the gastric mucosa: gastric pits, lumina of the glands, surface epithelium, glandular epithelial cells, and interglandular connective tissue. Fibrous granulation were also observed in some nodular lesion.

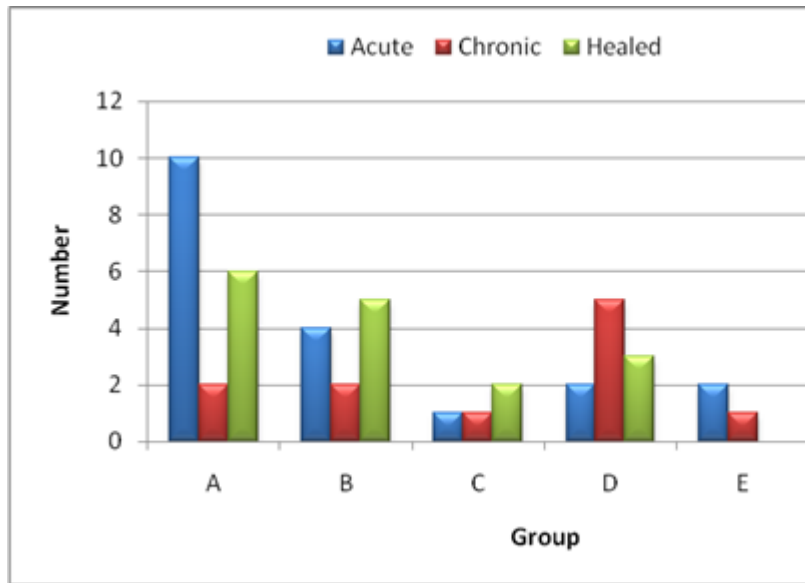
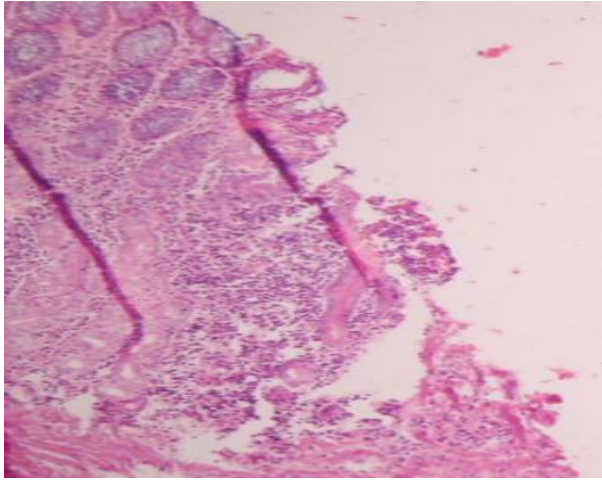


Figure 1: Types of gastric ulceration observed in the different groups

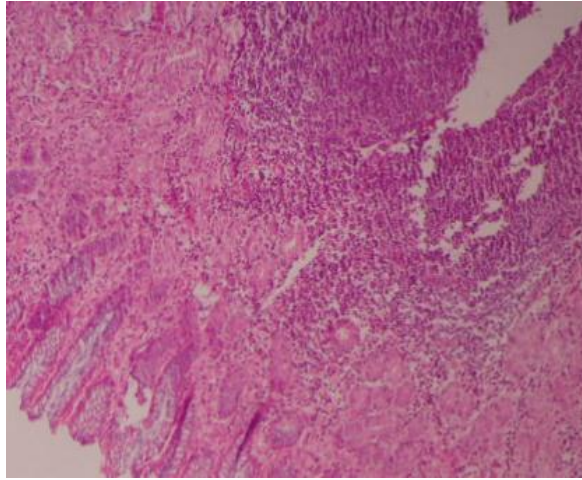
Table 1: Age, sex and distribution of ulcers and nodules of varying sizes in pig stomachs in groups A – E

Category	Groups				
	A	B	C	D	E
Sex	Male	Females	Males	Females, non Pregnant	Females, Pregnant
Age	8–12 months	8–12 months	12–36 months	12-36 month	12-36 months
Anatomic location of lesions					
Pars oesophagea	14	8	3	7	3
Cardia and Fundus	4	3	1	3	–
Normal	14	13	6	11	10
Total	32	24	10	21	13
% with lesion	56.3%	45.8%	40%	47.6%	23.1%

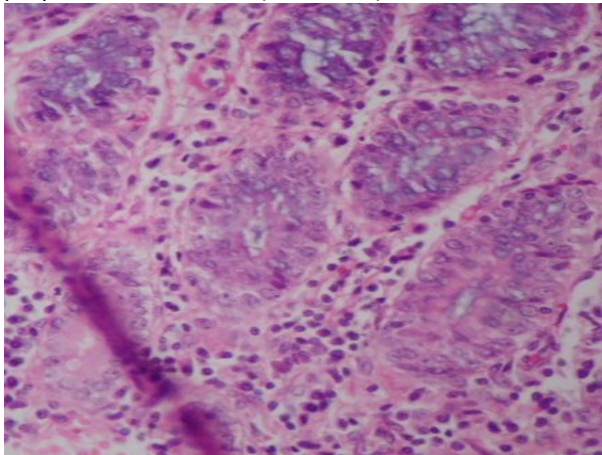
significant at <0.05



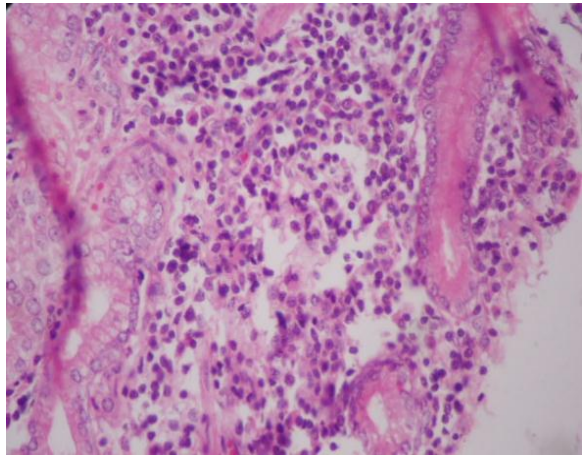
Plates I: Focal epithelial and glandular necrosis (ulcer) with accumulation of mononuclear cells in the lamina propria of the stomach (X100 H&E).



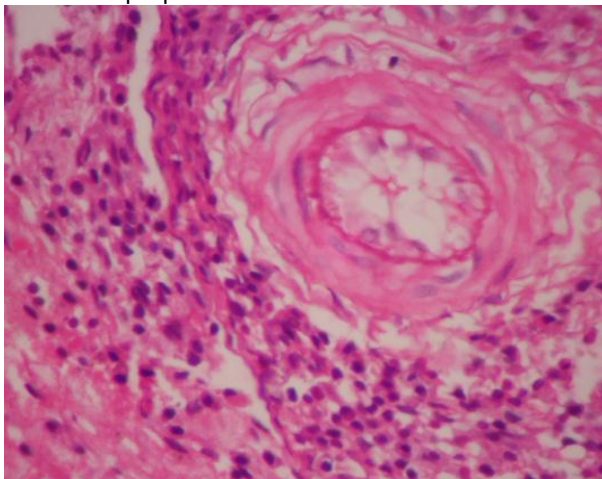
Plates II: Lymphoid aggregation in the submucosa of the stomach (X40 H&E).



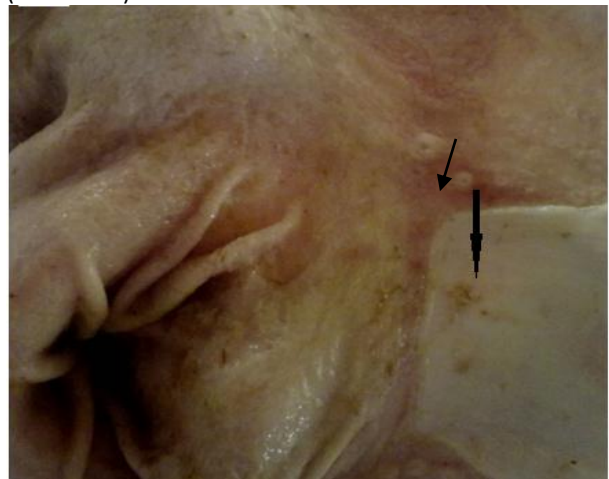
Plates III: Glandular degeneration and necrosis (X250 H&E) with accumulation of mononuclear cells in the lamina propria of the stomach



Plates IV: Massive mononuclear infiltration of the lamina propria and interglandular connective tissue. (X250 H&E)



Plates V: Healing ulcer: fibrous granulation with infiltration with macrophages, lymphocytes and plasma cells in the lamina propria. (X400 H&E)



Plates VI: There were nodular lesions (arrow) of varying sizes in the pars oesophagea of the stomach

Discussion

In this study, gastric lesions were predominantly those of ulcers with few being nodules of varying sizes and a few erosions. These lesions were observed in 46% of the stomachs of the slaughtered pigs examined. This condition often passes undiagnosed because of the dynamic nature of ulcers appearing and healing within a few days. It was not possible in this investigation to analyse the relationship between gastric ulcer and growth rate but most studies have reported no relationship between gastric ulcers severity at slaughter and growth rate, unless lesions are severe and chronic (Friendship, 1999).

From the results, there is a possible age than sex predisposition in the occurrence of gastric ulceration as higher percentage was observed in the grower pigs with younger pigs having a higher prevalence. The possible reason for this pattern cannot be easily arrived at however; it is an area to focus research on. Though the factors responsible for the distribution of the lesions in the mucosa of the pig stomach were not evaluated, it has been suggested by some workers that transport stress, foreign bodies in the feed and fasting of the animal prior to slaughter are possible contributory factors attributed to the higher incidence of ulcers hence severe ulcer can be useful in welfare assessment to reflect some of the standards of handling and husbandry (Friendship, 1999).

Observing most of the lesions in the *pars oesophagea* (76%) is similar to reports of other workers who found over 80% of market hogs with some type of lesion involving the *pars oesophagea*. (Makinde & Obwolo, 1990, Friendship, 1999). Although stomach lesions in pigs do occur in the glandular regions (Hermann *et al.*, 1995), but this tends to be uncommon and generally low in this study.

The high prevalence (46%) of gastric lesion observed in this study may have been due to poor hygiene practices on most farms, poor practice of routine deworming, transportation and handling stress before slaughter, and possibly infections. The prominent histopathological change observed is that of pin point ulcer, nodular gastritis and fibrous granulation may be associated with viral, bacteria, fungi and parasitic agents in this environment hence

the need to research into various predisposing factors and aetiopathogenesis of gastric lesions in monogastrics. Although the reoccurring histopathological lesions observed were glandular degeneration, fibrous granulation and lymphoid follicles with massive infiltration of the lamina with lymphocytes and plasma cells, the frequency of occurrence of such cells in the stomach being regarded as physiological or inflammatory has been described to be debatable (Hermann *et al.*, 1995). According to the German Society of Pathology (1989), the gastric mucosa should only be classed as normal if no lymphocytes, plasma cells or granulocytes can be detected in the lamina propria while the occurrence of isolated lymphocytes and plasma cells indicates minimal gastritis. On the other hand, the Sydney system (Price, 1991) describes a small number of uniformly distributed lymphocytes or plasma cells as physiological and a single neutrophilic granulocyte per biopsy viewed as normal. In this investigation however, there are some with minimal infiltration while others had massive infiltration of the lamina propria with those cells. Some also had lymphoid follicles similar to that described for dogs and cats (Hermann *et al.*, 1995). The presence of glandular degeneration accompanied by lymphocyte accumulation with fibrosis of the propria as observed in this study had also being observed in dogs and cats (Hermann *et al.*, 1995). Although the primary cause of the gastric lesions were not ascertained, this could be based on the technique employed in this investigation hence there is need to employ the use of special stains to detect fungi, parasites and *Helicobacter* species as described by other workers (Hermann *et al.*, 1995). Other workers had also implicated *Gastrospirillum* sp. isolated from the base of ulcers (Barbosa *et al.*, 1995) and *Helicobacter pylori* (Krakowka *et al.*, 1995; Hermann *et al.*, 1995; Cattoli *et al.*, 1999), hence the need to study the aetiopathogenesis of gastric lesions in monogastrics in this environment is crucial to the control.

In conclusion, gastric lesions may continue to be an important problem of swine industry hence efforts should be on the identification of likely aetiology and predisposing factors pigs and other monogastric with the aim of proposition of preventive strategies.

References

- Amory JR, Mackenzie AM & Pearce GP (2006). Factors in the housing environment of finisher pigs associated with the development of gastric ulcers. *Veterinary Record*, **158**:260-264.
- Anonymous (2012). The pig site. <http://www.thepigsite.com/>; retrieved 2012-12-11.
- Ayles HL, Friendship RM & Ball RO (1996). Effect of dietary particle size on gastric ulcers, assessed by endoscopic examination, and relationship between ulcer severity and growth performance of individual fed pigs. *Swine Health Production*, **4**: 211–216.
- Barbosa AJ, Silva JC, Nogueira AM, Paulino E. Jr. & Miranda CR (1995). Higher Incidence of *Gastrospirillum* sp. in Swine with Gastric Ulcer of the *Pars oesophagea*. *Veterinary Pathology*, **32**: 134.
- Cattoli G, van Vugt R, Zanoni RG, Sanguinetti V, Chiocchetti R, Gualtieri M, Vandenbroucke-Grauls CMJE, Gaastra W & Kusters JG (1999). Occurrence and characterization of gastric *Helicobacter* spp. in naturally infected dogs. *Veterinary Microbiology*, **70**: 239-250.
- Dionissopoulos L, Delange CFM, Dewey CE, Macinnes JI & Friendship RM (2001). Effect of health management strategy during rearing on grower-finisher pig performance and selected indicators of immune system stimulation. *Canadian Journal of Animal Science*, **81**:179-187.
- Friendship RM (1999). Gastric ulcers. In: Straw BE, D'Allaire S, Mengeling WL & Taylor DJ, (editors). *Diseases of Swine*, 8th edition. Ames, Iowa: Iowa State University Press; Pp 685-694.
- German Society of Pathology (1989). Report of the German Society for Pathology. Gastritis: Graduation and Classification. *Pathologie*, **10**: 194-196
- Hermann W, Kregel K, Breuer W & Lechner J (1995). *Helicobacter-like* Organisms: Histopathological Examination of Gastric Biopsies from Dogs and Cats. *Journal Comparative Pathology*, **112**: 307-318
- Krakovka S, Eaton KA, Rings DM (1995). Occurrence of gastric ulcers in gnotobiotic piglets colonized by *Helicobacter pylori*. *Infection and Immunity*, **63**: 232-235.
- Makinde MO & Obwolo MJ (1990). Abattoir survey of gastric ulcer in pigs in Zimbabwe. *Zimbabwe Veterinary Journal*, **21** (3):116-123.
- Pfeiffer CJ (1992). A review of spontaneous ulcer disease in domestic animals: chickens, cattle, horses, and swine. *Acta Physiologia Hungarica*, **80**(1-4): 49-58.
- Price AB (1991). The Sydney system: histological division. *Journal Gastroenterology and Hepatology*, **6**: 209-222.
- Wondra KJ, Hancock JD, Behnke KC, Hines RH, Stark CR (1995). Effects of particle size and pelleting on growth performance, nutrient digestibility, and stomach morphology in finishing pigs. *Journal of Animal Science*, **73**:757–763.